

## **GENERAL INFORMATION**

### **THE JOURNAL:**

This is an official publication of the KMCT Dental College, Manassery P.O., Mukkom, Kozhikode 673 602, Kerala, India. The journal caters to scientific research and its application to practice for clinicians. This is a quarterly publication, with 4 issues per year.

### **AUTHORS:**

Submit your manuscript to [dental@kmct.edu.in](mailto:dental@kmct.edu.in)

### **SUBSCRIPTION:**

Subscription to Dental Bites comprises of 4 issues per year along with postal charges. Annual Subscription fee for 4 issues is Rs. 2000.

### **DISCLAIMER:**

All materials published in this journal undergo peer review. The views expressed in the articles are solely of the authors. Neither the editor nor the publisher of Dental Bites, or any other party involved in the preparation of the material contained in this journal represent or warrants that the information contained herein is in every aspect accurate or complete.

### **EDITORIAL OFFICE:**

**Dr. Manoj Kumar K. P**  
Editor, Dental Bites  
KMCT Dental College  
Manassery P.O., Mukkom  
Kerala, India

# DENTAL BITES

VOLUME 5, ISSUE 2

*April-June, 2018*

*A publication of*



Manassery P.O., Mukkom, Calicut-673602, Kerala  
Phone (0495) 229 0690/229 0693, Fax (0495) 229 4726

E-mail: [dental@kmct.du.in](mailto:dental@kmct.du.in), Web: [www.kmct.edu.in](http://www.kmct.edu.in)

**MANAGING DIRECTOR**

**DR. K.M. NAVAS**

*Executive Trustee  
KMCT Group of Institutions*

**CHIEF EDITOR**

**DR. MANOJ KUMAR K. P**

*Principal  
KMCT Dental College*

**EXECUTIVE EDITOR**

**DR. SAMEERA G. NATH**

*Reader, Dept. of Periodontics*

**ASSOCIATE EDITORS**

**DR. MARIUM RAHEEMA**

*Reader, Dept. of Pedodontics & Preventive Dentistry*

**DR. ARUN PAUL**

*Senior Lecturer, Dept. of Public Health Dentistry*

**EDITORIAL BOARD MEMBERS**

**DR. AUSWAF AHSAN**, *Dept. of Oral Medicine & Radiology*

**DR. RAJEESH MOHAMMED**, *Dept. of Oral Pathology*

**DR. BINU PURUSHOTHAMAN**, *Dept. of Orthodontics & Orofacial Orthopaedics*

**DR. HARISH KUMAR V. V.**, *Dept. of Periodontics*

**DR. BENNY JOSEPH**, *Dept. of Oral & Maxillofacial Surgery*

**DR. RAMESH KUMAR M.**, *Dept. of Conservative Dentistry & Endodontics*

**DR. PRATHYUSHA**, *Dept. of Pedodontics & Preventive Dentistry*

**DR. SWAPNA C.**, *Dept. of Prosthodontics*

**DR. DHANYA MURALIDHARAN**, *Dept. of Public Health Dentistry*

## EDITORIAL

*“If we can really understand the problem, the answer will come out of it. Because the answer is not separate from the problem”*

*-Jiddu Krishna Murthi*

The above quote can be very well related to the present situation of dental education system across the country. The dental colleges along the length and breadth of the small state of Kerala stands testimonial of the volume of young graduates entering the profession each year. Dentistry has provided reasonably good financial security and social acceptance even to the newly graduated students. The early decades of our twenty-first century have witnessed a steady decline in the standard of under graduates passing out each year, which has largely contributed to reduced opportunities and employability to freshers. This has been resulting in the decrease in number of students who want to pursue their career as a Dentist.

As those who have been through the ups and downs of this career, we should be proactive in keeping up the nobility and dignity of our profession. For achieving this goal, we must train our students not only for securing mere degrees but also to become better professionals who possess sound clinical skills, clear and logical thinking and above all, a genuine interest in the subject. As it is said, the key is in your hand, but you have to find the door.

Dr Manoj Kumar KP

Chief Editor

## TABLE OF CONTENTS

### ***Literature Review***

1. The emerging nanos- A dawn of a novel arena in dentistry *pg 5*  
*Dr. Festi Lova*
2. Smart dental materials *pg 11*  
*Dr. Fathima Shirin*

### ***Case Report***

3. A simple method of rehabilitating an acquired maxillectomy defect patient with hollow bulb obturator: A case report *pg 19*  
*Dr. Dhanya Preman*
4. “Be wise on early rise”-Natal and neonatal teeth *pg 25*  
*Dr. Prathyusha P*
5. Endodontic management of mandibular first molar with radix endomolaris & five canals: A case report *pg 32*  
*Dr. Ramesh Kumar M*

### ***Awards & Achievements*** *pg 36*

## THE EMERGING NANOS- A DAWN OF A NOVEL ARENA IN DENTISTRY

\*Dr. Festi Lova, \*\* Dr. Auswaf Ahsan

### Abstract

Nanotechnology provides a wide horizon in sculpturing eternal changes in the fields of medicine and dentistry. It's an unavoidable emerging science. A day may soon come when nanodentistry will succeed in maintaining near-perfect oral health through the aid of nanorobotics, nanomaterials and biotechnology. This article enlightens about the potential application of nanotechnology in dentistry and illustrates their potentially far reaching impact on clinical dental practice.

**Key Words:** Nanorobots, Nanoterminators, Nanoshells

**Corresponding Author:** Dr. Festi Lova

---

*\*Post Graduate Student, \*\*Professor & Head, Dept. of Oral Medicine and Radiology, KMCT Dental College, Manassery, Kozhikode 673602*

### Introduction

Nanotechnology or nanoscience is the branch of science at a subatomic or molecular level which deals with dimensions and tolerances of less than 100 nanometers. It deals with the manipulation of individual atoms, molecules and chemical bonds between them. It is used in various medical fields of pharmacological research, dental therapeutics, clinical diagnostic procedures, to supplement immune system, to detect proteins, in cryogenic storage of biological tissues, in probing of DNA structure, tissue engineering, for tumour destruction, in MRI, contrast enhancement and the list goes endless.

### History

The origin of the word “nano” is from the Greek terminology, which means “dwarf”. The vision of nanotechnology was first shared by the American Physicist Richard

Feynman. He was considered to be the father of nanotechnology.<sup>1</sup> In 1974, Japanese scientist Norio Taniguchi of Tokyo University of Science introduced the term nanotechnology. In the year 2000, Robert Freitas started using the term nanodentistry.<sup>2</sup>

### Concept of Nanotechnology

Nanorobots or nanobots are tiny spider like software controlled machines, often used to perform specialized jobs (Fig 1). It is smaller than a nucleus of a cell, which makes it fit anywhere, that are hard to reach by hand or with any other technology.

Drug molecules transported through the body by circulatory system may cause undesirable adverse effects in untargeted regions. Nanobots are exceptionally helpful in delivering the drug molecules to the predetermined targets. The capacity of

nanobots to recognize unhealthy tumour cells and destroying them wherever they are located is highly appreciable in the field of cancer therapeutics.<sup>3</sup>

As per the nanorobotic theory, the microscopic size of nanorobots makes it necessary for a very large number of them, to work together to perform in both microscopic and macroscopic errands.<sup>4</sup>

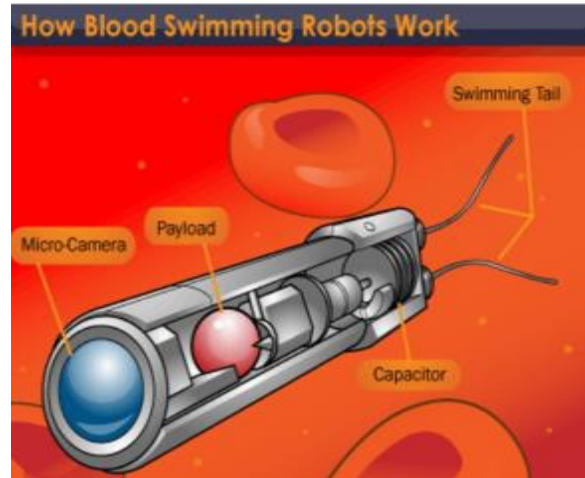


**Fig 1: Nanorobot**

**Components of nanorobots**

Nanorobots often have a nanocomputer on board, which will stock & perform pre planned errands and also responds to an external stimuli from an external auditory devices. A navigational network installed in the body of nanobots, provides high topographical accuracy to all the circulating nanorobots and keep track of the various devices in the body and interacts with other nonobots in action. It has an inbuilt camera which gives the exact location of the nanorobots present within the body.

Assembling nanorobots involve actuators, sensors, power, control, communications & interfacial signals across spatial scales and between organic and inorganic systems (Fig 2).<sup>4</sup>



**Fig 2 : Components of nanorobot**

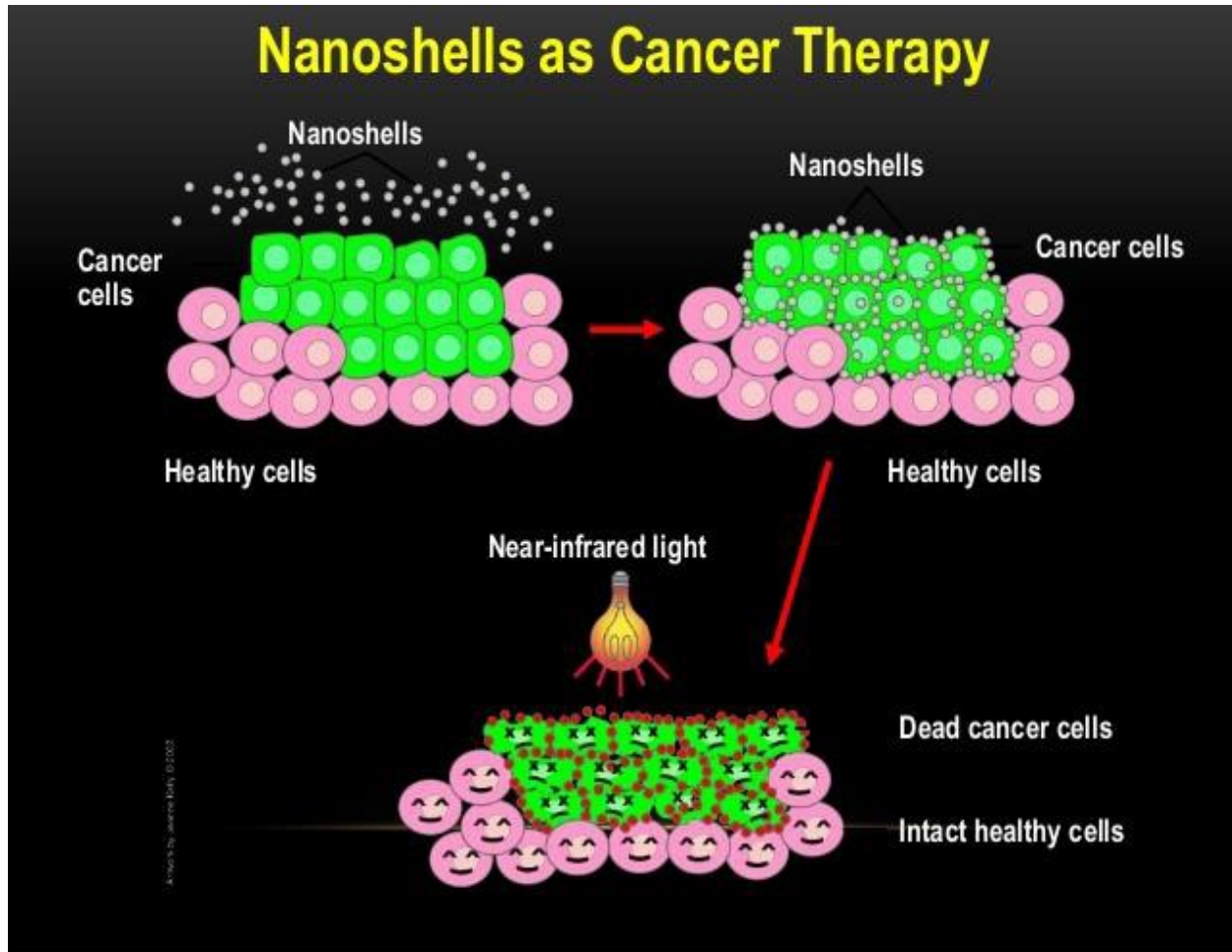
**Mechanism of action**

Once inside the human body, nanorobots uses their specific motility mechanisms to crawl or to swim through the human tissue or to penetrate through the tissue with navigational precision and reaches the target sites as it was pre programmed in the nanocomputer on board. It utilizes the internal sources (the energy liberated by the radioactive fragments attached to the nanorobot body) and the external sources (such as the host’s body heat or the electrolytes and the metabolism of the glucose in the blood flow) of energy. The onboard nanocomputer executes the pre programmed instructions in response to local sensor stimuli. Also, the medical professional can issue some strategic orders directly to the nanorobots in vivo via acoustic signals.<sup>5,6</sup> When the target of the nanorobot is achieved, they are retrieved by



granting their exit via the usual human excretory channels. They may also be

cleared away by active scavenger systems called nano-terminators.<sup>4</sup>



**Fig 3: Nanoshells as cancer therapy**

**Application of nanotechnology in dentistry:**

**(a) Diagnosis and treatment of oral cancer**

Nanotechnology can be used for the early disease identification at the cellular and molecular levels and to quantify toxic molecules and the tumor cells. Exosome is a membrane bound secretory vesicle, which is present in body fluids, contain proteomic & genomic markers, whose level is elevated in malignancy. This marker has been studied

by using atomic force microscopy which employs nanoparticles. Nano electro mechanical system, oral fluid nanosensor tests and optical nanobiosensors can also be used in the diagnosis of oral cancer. Nano shells, which are mini beads, have an outer metallic layers that selectively destroys cancer cells and is highly effective in cancer therapeutics (Fig 3).<sup>7</sup> Nanoparticle-coated, radioactive sources are also used in brachytherapy.



### **(b) Dental implants**

Bone is considered to be a natural nanostructure that is composed of organic compounds (mainly collagen) and reinforced with inorganic compounds. Nanotechnology aims to mimic the natural structure present on the bone, for the development of nano bone.

Roughening the implant surface at the nanosurface level enhances osteoblast adhesion and thus provides an increased implant surface area that can react with the biologic environment. Nanomaterials also helps in the repair and regeneration of cellular tissue in bone, which enhances osteoblast proliferation. Bone grafts with better characteristics can be developed with the use of nanocrystalline hydroxyapatite materials, which stimulates the cell proliferation required for periodontal tissue regeneration.<sup>8</sup> Hydroxyapatite nano crystals, show a loose microstructure, with nanopores, which helps in adsorbing protein.<sup>8</sup>

### **(c) Oral surgery**

Nanoanesthesia is a most modern trend used in the surgical procedures for a fast acting anxiety free anesthesia. In nanoanesthesia, gingiva of the patient is loaded with a colloidal suspension containing millions of active micron-sized dental nanorobots, that responds to the input supplied by the dentist. Once when these nanobots contact the surface of the crown or mucosa, the ambulating nanorobots travels to the pulp via the gingiva sulcus, lamina propria & the dentinal tubules, guided by chemical gradient and temperature differentials controlled by the dentist.

As soon as they reach the pulp, they shut down all sensations by establishing control over nerve-impulse traffic in any tooth that requires treatment.

Nano particles are also used as sterilizing solution in the form of nanosized emulsified oil droplets that bombard pathogens.<sup>9</sup>

Suture needles incorporating nano-sized stainless steel crystals and nano tweezers provide a wide horizon for cell surgery in the near future.

### **(d) Restorative procedures**

Nanosolutions with a unique and dispersible nanoparticle can be used in bonding agents. Nanofiller technology has enabled the production of nanofill composites by bringing together the esthetic features of microfill composites and the mechanical features of hybrid composites. Composite resins with nanofillers are used in wider restorative areas as they are easy to shape, produce a smooth surface after the polishing process & superior esthetic features with high degree of strength and resistance to abrasion. The fillers in nano composites have higher translucency since they are smaller than the wavelength of light, thereby allowing the generation of more esthetic restorations with a vast range of colour options.<sup>10</sup> A toothpaste containing nanosized calcium carbonate enables remineralization of early enamel lesions.

### **(e) Prosthodontics**

Nanofillers are integrated into vinylpolysiloxanes, producing a unique siloxane impression material that has a better flow and an enhanced precision detail.

### **(f) Orthodontic Treatment**

Orthodontic nanorobots could directly manipulate periodontal tissues, allowing rapid & painless tooth straightening, rotating & vertical repositioning as well as rapid tissue repair within minutes to hours. A reduction in frictional force produced by orthodontic movement by coating the orthodontic wire with inorganic fullerene-like tungsten disulfide nano particles (IF-WS) known for their excellent dry lubrication properties.<sup>11</sup> Orthodontic brackets coated with the nitrogen-doped titanium oxide thin film showed high antimicrobial & bacterial adhesive properties against normal oral pathogenic bacteria through visible light, which is effective in prevention of enamel demineralization & gingivitis in orthodontic patients.<sup>12</sup>

### **(g) Periodontics**

Dentifrobots in the form of mouthwash or toothpaste left on the occlusal surface of teeth can clean organic residues by moving throughout the supragingival and subgingival surfaces, metabolizing trapped organic matter into harmless & odorless vapors and performing continuous calculus debridement.

### **(h) Dental Imageology**

Charge-coupled devices (CCD) & complementary metal oxide semiconductors (CMOS), also known as Active Pixel Sensors (APS), traditionally use scintillators for conversion of X-ray photons to visible light that in turn expose the sensitive digital image receptors. During this conversion process, light is scattered, resulting in the loss of utilization efficiency which will

eventually contribute to decreased image resolution. The new nanophosphor scintillator screen also converts the X-ray photons to light, but it captures the light by way of reflection and micro channelling to light collecting devices and electronic detectors. Radiation dose obtained using digital radiography with nanophosphor scintillators is diminished and high quality images are obtained.<sup>13</sup>

### **Conclusion**

Nanotechnology is set to revolutionize clinical dental practice. It is considered to be a novel method for disease diagnosis and management. The optimal utilization of opportunities offered by nanotechnology in clinical dental practice facilitates more patient acceptability and offers quality treatment in oral health care.

### **References**

1. Selin C. Expectations and the Emergence of Nanotechnology. *Science, Technology, & Human Values*. 2007 Mar;32(2):196-220.
2. Mikkilineni M, Rao AS, Tummala M, Elkanti S. Nanodentistry: New buzz in dentistry. *Eur J Gen Dent*. 2013 May 1;2(2):109.
3. Freitas RA., Jr Nanotechnology, nanomedicine and nanosurgery. *Int J Surg*. 2005;3:243-6.
4. Mitthra S, Karthick A, Anuradha B, Mensudar R, Sadhana KR, Varshini GN. Nanorobots—A small wonder. *Biosci Biotech Res*. 2016 Dec 22;13:2131-4.
5. Shetty NJ, Swati P, David K. Nanorobots: Future in dentistry. *The Saudi Den J*. 2013 Apr 30;25(2):49-52.
6. Mikkilineni M, Rao AS, Tummala M, Elkanti S. Nanodentistry: New buzz in dentistry. *Eur J Gen Dent*. 2013 May 1;2(2):109.

7. Freitas RA., Jr Nanodentistry. *J Am Dent Assoc.* 2000; 131:1559–65.
8. Park JW, Kim HK, Kim YJ, An CH, Hanawa T. Enhanced osteoconductivity of micro-structured titanium implants (XiVE S CELLplus) by addition of surface calcium chemistry: A histomorphometric study in the rabbit femur. *Clin Oral Implants Res.* 2009;20:684–90.
9. Abiodun-Solanke, DM Ajayi, and AO Arigbede. Nanotechnology & its Application in Dentistry. *Ann Med Health Sci Res.* 2014 Sep-Oct; 4(Suppl 3): S171–7.
10. D’Attilio M, Traini T, Di Iorio D, Varvara G, Festa F, Tecco S. Shear bond strength, bond failure, and scanning electron microscopy analysis of a new flowable composite for orthodontic use. *Angle Orthod.* 2005;75:410–5.
11. Redlich M, Katz A, Rapoport L, Wagner HD, Feldman Y, Tenne R. Improved orthodontic stainless steel wires coated with inorganic fullerene-like nanoparticles of WS(2) impregnated in electroless nickel-phosphorous film. *Dent Mater.* 2008;24:1640–6.
12. Cao B, Wang Y, Li N, Liu B, Zhang Y. Preparation of an orthodontic bracket coated with an nitrogen-doped TiO (2-x) N (y) thin film and examination of its antimicrobial performance. *Dent Mater J.* 2013;32:311–6.
13. Mupparapu M. New nanophosphor scintillators for solid-state digital dental imagers. *Dentomaxillofac Radiol.* 2006;35: 475–6.

## SMART DENTAL MATERIALS

\* Dr.Fathima Shirin.V, \*\*Dr.Elsy.P.Simon,  
\*\*\*Dr.M.Ramesh Kumar, \*\*\*\*Dr.Ravi.S.V

### Abstract

Smart materials are materials that have properties which may be altered in a controlled fashion by stimuli, such as stress, temperature, moisture, pH, and electric or magnetic fields. Smart materials respond to stimuli by altering one or more of their properties. Smart behavior occurs when a material can sense some stimulus from its environment and react to it in a useful, reliable, reproducible, and usually reversible manner. These properties have a beneficial application in various fields including dentistry. Shape memory alloys, zirconia, and smart seal are examples of materials exhibiting a smart behaviour in dentistry. There is a strong trend in material science to develop and apply these intelligent materials. These materials would potentially allow new and ground breaking dental therapies with a significantly enhanced clinical outcome of treatments.

**Key Words:** Smart materials, responsive materials, review

**Corresponding Author:** Dr. Fathima Shirin V

*\*Post Graduate Student, \*\*Professor, \*\*\*Professor & Head \*\*\*\*Reader, Dept. of Conservative Dentistry, KMCT Dental College, Manassery, Kozhikode 673602, Kerala, India.*

### Introduction

Smart materials are designed materials that have one or more properties that can be significantly changed in a controlled fashion by external stimuli, such as stress, temperature, moisture, pH, and electric or magnetic fields.<sup>1</sup> Smart materials have been around for many years and they have found a large number of applications. The use of the terms “smart” and “intelligent” to describe materials and systems came from the USA and started in the 1980s despite the fact that some of these so-called smart materials had been around for decades. Early smart material applications started with magnetostrictive technologies. This involved the use of nickel as a sonar source during

World War I to find German U-boats by allied forces. Smart behaviour occurs when a material can sense some stimulus from its environment and react to it in a useful, reliable, reproducible, and usually reversible manner. Some researchers insist that no material by itself is truly smart, as opposed to being simply responsive. They insist that being smart is not just a matter of producing a response in proportion to a stimulus, but includes principles such as adaptation and feedback. Others draw a distinction between merely smart and truly intelligent, in the sense of being able to do things like make decisions or repair oneself. No artificial materials are yet intelligent in this sense.

This paper aims to describe the various materials in dentistry that exhibit some sort of smart behaviour.

### Definition

McCabe Zrinyi defined smart materials as "Materials that are able to be altered by stimuli and transform back into the original state after removing the stimuli". The stimuli can be derived from temperature, pH, moisture, stress, electricity, chemical or biomedical agents and magnetic fields. A key feature of smart behaviour includes an ability to return to the original state after the stimulus has been removed. Smart materials are highly responsive and have a great capacity to sense and respond to any environmental change. Hence these materials are also known as -Responsive Materials.

### Properties of smart materials

Smart materials sense changes in the environment around them and respond in a predictable manner.<sup>2</sup> In general, these properties are:

- Piezoelectric-<sup>3</sup> when a mechanical stress is applied, an electric current is generated.
- Shape memory- <sup>4,5</sup> after deformation these materials can remember their original shape and return to it when heated.
- Thermo chromic - these materials change color in response to changes in temperature.
- Photo chromic - these materials change color in response to changes in light conditions.

- Magneto rheological - these are fluid materials become solid when placed in a magnetic field.
- PH sensitive - materials which swell/ collapse when the pH of the surrounding media changes.<sup>6</sup>

Bio film formation- presence of bio film on the surface of material alters the interaction of the surface with the environment.<sup>7</sup>

### Classification of smart materials

#### I. Passive Smart Restorative Materials:

Respond to external change without external control.

Eg;- GIC, Resin Modified GIC, Compomer, Dental Composites

#### II. Active Smart Restorative Materials:

Utilize a feedback loop to enable them to function like a cognitive response through an actuator circuit.

1. Restorative Dentistry  
Eg: Smart GIC, Smart composites, Ariston Phc
2. Prosthetic Dentistry  
Eg: Smart ceramics, Smart impression materials
3. Orthodontics  
Eg: Shape memory alloys.
4. Pediatric and Preventive Dentistry  
Eg: Fluoride releasing pit and fissure sealants, ACP releasing pits and fissure sealants
5. Endodontics  
Eg: NiTi rotary instruments.

6. Smart Fibers for Laser Dentistry  
Eg: Hollow-core Photonic-Fibers

Their applications are as follows:-

**Amorphous calcium phosphate (ACP)**

ACP is an antecedent in the biological formation of hydroxyapatite (HAP). It has both preventive and restorative properties, which justify its use in dental cements and adhesives, pit and fissure sealants and composites.<sup>8</sup>

*Mechanism of action:* At neutral or high pH, ACP remains in its original form in the oral environment. But when the surrounding pH drops to a level where it can demineralize the tooth surface, i.e., at or below 5.8 (critical pH), ACP converts into crystalline HAP, thus replacing the HAP crystal lost to the acid. These released ions will merge within seconds and form a gel. In less than 2 min this gel becomes amorphous crystals, resulting in calcium and phosphate ions. Crystalline HAP is the final stable product in the precipitation of calcium and phosphate ions from neutral or basic and it neutralizes the acid and buffer the pH.

*Advantages*

1. It acts as a reinforcement of the natural defense mechanism of the tooth only when needed.
2. It has long life and there is no wash out.
3. Patient compliance is not required.

**Casein phosphopeptide (CPP)**, a milk derivative is complexes with ACP and this CPP - ACP complex is used in dentifrices as a remineralizing agent in the reversal of incipient white spot lesions under the name

ReCaldent. It is commercially available as GC tooth mousse plus ® (The University of Melbourne, Victoria, Australia).

**Smart composites**

It is a light-activated alkaline, nano filled glass restorative material. It releases calcium, fluoride and hydroxyl ions when intraoral pH values drop below the critical pH of 5.5 and counteracts the demineralization of the tooth surface and also aids in remineralization.<sup>9</sup> The material can be adequately cured in bulk thicknesses of up to 4 mm. It is recommended for the restoration of class 1 and class 2 lesions in both primary and permanent teeth.

Stimuli responsive-smart composites may be useful with various applications including the “release-on-command” of remineralising elements or antimicrobial products and fluorides to fight microorganisms or secondary caries. Composites containing amorphous calcium phosphate (ACP) are usually considered as smart composites. Smart composites have the advantages of excellent sustained release of calcium and phosphate ions into the stimulated saliva and excellent biocompatibility. Due to its extended time release of calcium and phosphate and bio activity, they have high prophylactic value in preventing caries by highly reducing demineralisation and promoting remineralisation of tooth. Microbes producing acids can decrease the pH resulting in the loss of hydroxyapatite from the tooth. ACP is stable at neutral and high pH, but at a low pH (5.8 or less) it gets converted into crystalline hydroxyapatite and later gets precipitated thus replacing the



lost hydroxyapatite. Composites having alkaline glass fillers with calcium and fluoride release can prevent demineralisation contiguous to the restorations. They also reduce the growth of bacteria which is cariogenic by the neutralising and buffering action on the acid produced by the microbes. Recently introduced product wherein nano DCPA (dicalcium phosphate anhydrous) and TTCP (tetra calcium phosphate) fillers have been introduced with increased strength of the material which doesn't compromise the Ca and PO<sub>4</sub> releasing property. These newer composites can increase the Ca and PO<sub>4</sub> release while the pH is reduced from neutral to a cariogenic pH of 4.

Eg: Ariston pH control - introduced by Ivoclar - Vivadent (Liechtenstein) Company.

### **Smart ceramics**

These are metal - free biocompatible life like restorations that allows them to blend well with the surrounding natural dentition.<sup>10</sup> They made the process of restoring teeth to natural form easy and predictable.<sup>11</sup> It was introduced by Cercon “all ceramic teeth bridge” was materialised after the introduction of smart ceramics. Though ceramics were available for a long time to fabricate crowns and bridges, they were used with a metal substructure as porcelain fused metal crowns. These porcelain fused metal crowns reduce the aesthetic quality of the restoration. The introduction of high tech ceramic, zirconia has brought the fabrication of crowns and bridges without the metal substructure. Zirconia is a polycrystalline ceramic where all of the atoms are arranged in regularly crystalline arrays. This

arrangement provides greater resistance to the development and propagation of crack through it compared to other forms of ceramics. Hence, zirconia are stronger and tougher than other ceramics . Zirconia takes advantage of toughness, strength, biocompatibility and reliability and they have been used highly in all ceramic teeth frameworks, dental prosthesis, implant supported crowns, implant abutments and root canal posts

Eg: Cercon Zirconium Smart Ceramic System.

### **Smart impression materials**

These materials exhibit more:

- Hydrophilic to get void free impression.
- Shape memory during elastic recovery resists distortion for more accurate impression, toughness resists tearing.
- Snap - set behavior results in precise fitting restorations without distortion.
- Cut of working and setting times by at least 33%.
- Viscosity-materials with low viscosity have high flow.<sup>12</sup>

Eg: Imprint™ 3 VPS, Impregim™ , Aquasil ultra (3M ESPE Dental Products, USA).

### **Smart glass ionomer cement (RMGICs)**

The smart behavior of GIC was first suggested by Davidson.<sup>13</sup> It is related to the ability of a gel structure to absorb or release solvent rapidly in response to a stimulus such as temperature, change in pH etc. The number and size of pores with the cement can be controlled by the method of mixing



conveniently measuring using micro-computed tomography scanning.<sup>14</sup> These smart ionomer mimic the behavior of human dentin. Resin modified glass ionomer cement, compomer or giomer also exhibit these smart characteristics.

A wide range of temperature fluctuations due to the consumption of hot and cold foods and fluids takes place in the oral cavity. Therefore, the restoration materials placed in the oral cavity are exposed to thermal changes. Thermal changes of a substance can be described by coefficient of thermal expansion (CTE). It is desirable and acceptable to have a CTE value for the restoration material which is comparable with that of the tooth structure to reduce the chances of stress concentration and microleakage. When heating and cooling between 20°C and 50°C in wet conditions, little or no dimensional change was observed by glass-ionomers. Material showed a marked contraction in dry conditions above 50°C. This behaviour is explained by the mechanism of fluid flow in the dentinal tubules. In wet conditions, heating expansion is compensated by the fluid flow to the surface of the material to produce a balancing dimensional change which is reversed on cooling. In dry conditions, loss of fluid flow from the material causes contraction on heating. Hence, the glass-ionomer materials is said to be mimicking the behaviour of human

dentine through a type of smart behavior. Eg: GC Fuji IX GP EXTRA (Zahnfabrik Bad Söckingen, Germany).

### **SMAs**

These alloys have exceptional properties such as super elasticity, shape memory, good resistance to fatigue and wear and relatively good biocompatibility(15). Ni-Tinol was introduced in orthodontics in 1970s and is used in fabrication of brackets. Wires exhibiting shape memory behavior at mouth temperature normally contain copper and or chromium in addition to nickel and titanium.

Eg: Ni-Ti alloy.

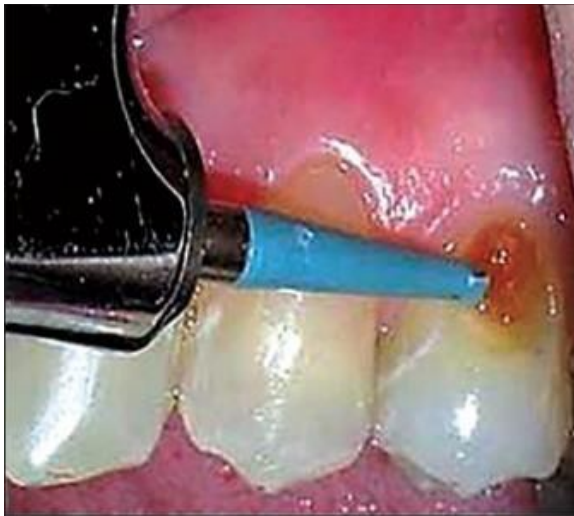### **Nickel-titanium (Ni-Ti) rotary instruments**

The introduction of Ni-Ti in rotary endodontic has made instrumentation easier and faster than conventional hand instrumentation during biomechanical preparation of root canal treatment. The advantage of using rotary Ni-Ti (16) files are less chances of file breakage within the canal during instrumentation, less fatigue to the operator, less transportation, decreased incidence of canal aberration and minimal post-operative pain to the patient.

Eg: Ni-Ti rotary files.

### **Smart prep burs**

These are polymer burs that cuts only infected dentin. (17)The affected dentin which has the ability to remineralize is left intact. Over cutting of tooth structure that usually occurs with conventional burs can be avoided by the use of these smart preparation burs.

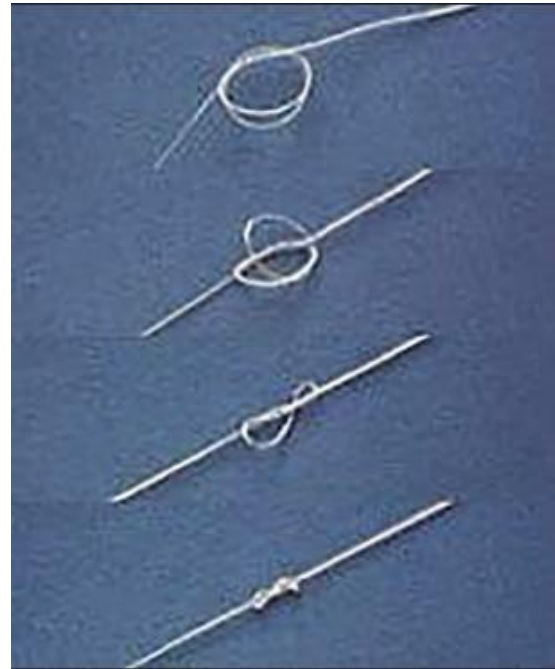

**Fig 1: Smart prep burs**

Eg: SS White (145 Towbin Avenue, Lakewood, Newjersey, 08701, USA) diamond and carbide preparation kit.

### Smart sutures

These sutures are made up of thermoplastic polymers that have both shape memory and biodegradable properties.<sup>18</sup> They are applied loosely in its temporary shape and the ends of the suture were fixed. When the temperature is raised above the thermal transition temperature, the suture would shrink and tighten the knot, applying the optimum force. This thermal transition temperature is close to human body temperature and this is of clinical significance in tying a knot with proper stress in surgery. Smart sutures made of plastic or silk threads covered with temperature sensors and micro-heaters can detect infections.<sup>19</sup> Eg: Novel MIT Polymer (Aachen, Germany).



**Fig 2: Smart sutures**

### Smart antimicrobial peptide

A pheromone-guided "smart" antimicrobial peptide is targeted against killing of *Streptococcus mutans* which is the principal microorganism responsible for the cause of dental caries.<sup>20</sup> The concept of tissue regeneration wherein the tissues can be re grown in the oral cavity is an emerging new technology.<sup>21</sup> The BRAX-I gene<sup>22</sup> has been isolated along these lines has been isolated that is thought to be responsible for control on enamel growth. Eg: Pheromone guided "smart" antimicrobial peptide.

These smart materials are used to achieve maximum advantage by conventional restorative techniques in dentistry. The use of computer-aided design/computer-aided manufacturing<sup>23</sup> technology in designing of cavity preparation is much easier and more adaptable to each tooth, rather than the conventional approach.

## Conclusion

The recent advances in the design of smart materials have created novel opportunities for their applications in biomedical fields. These numerous applications of —Stimuli Responsive or Smart Materials, no wonder tells us that these materials hold a real good promise for the future. The most sophisticated class of smart materials in the foreseeable future will be that which emulates biological systems.

## References

1. [http://en.wikipedia.org/wiki/Smart material](http://en.wikipedia.org/wiki/Smart_material)
2. Smart materials and systems. *Postnote* 2008;299:1-4.
3. Allameh SM, Akogwu O, Collinson M, Thomas J, Soboyejo WO. Piezoelectric generators for biomedical and dental applications: Effects of cyclic loading. *J Mater Sci Mater Med* 2007;18:39-45.
4. Gil FJ, Planell JA. Shape memory alloys for medical applications. *Proc Inst Mech Eng H* 1998;212:473-88.
5. Lendlein A, Langer R. Biodegradable, elastic shape-memory polymers for potential biomedical applications. *Science* 2002;296:1673-6.
6. Stayton PS, El-Sayed ME, Murthy N, Bulmus V, Lackey C, Cheung C, et al. 'Smart' delivery systems for biomolecular therapeutics. *Orthod Craniofac Res* 2005;8:219-25.
7. Rolland SL, McCabe JF, Robinson C, Walls AW. In vitro biofilm formation on the surface of resin-based dentine adhesives. *Eur J Oral Sci* 2006;114:243-9.
8. Dube M, Ponnappa KC. Smart ART! *J Int Oral Health* 2009;1:52-7.
9. Xu HH, Weir MD, Sun L, Takagi S, Chow LC. Effects of calcium phosphate nanoparticles on Ca-PO<sub>4</sub> composite. *J Dent Res* 2007;86:378-83.
10. Little DA. A smart ceramics system for expanded indications. *Inside Dent* 2012;8:1-4.
11. Little DA, Crocker JJ. Clinical use of a new metal free restorative technology. Case reports. *DENTSPLY Asia update*. 2003;1-3.
12. Terry DA, Leinfelder KF, Lee EA, James A. The impression: A blue print to restorative success. *Int Dent SA* 2006;8:12-21.
13. Davidson CL. Glass ionomer cement, an intelligent material. *Bull Group Int Rech Sci Stomatol Odontol* 1998;40:38-42.
14. Nomoto R, Komoriyama M, McCabe JF, Hirano S. Effect of mixing method on the porosity of encapsulated glass ionomer cement. *Dent Mater* 2004;20:972-8.
15. Friend C. Smart materials: The emerging technology. *Mater World* 1996;4:16-8.
16. Lieutenant Brent JC, Mc Clanahan S. Endodontic rotary nickel-titanium instrument systems. *Clin Update* 2003;25:15-6.
17. Dammaschke T, Rodenberg TN, Schäfer E, Ott KH. Efficiency of the polymer bur SmartPrep compared with conventional tungsten carbide bud bur in dentin caries excavation. *Oper Dent* 2006;31:256-60.
18. Yuan P. Biodegradable shape-memory polymers. *Literature Seminar*; 2010 September.

19. Patel P. Smart sutures that detect infections. *Bio Med News* 2012.
20. Eckert R, He J, Yarbrough DK, Qi F, Anderson MH, Shi W. Targeted killing of *Streptococcus mutans* by a pheromone-guided "smart" antimicrobial peptide. *Antimicrob Agents Chemother* 2006;50:3651-7.
21. Galler KM, D'Souza RN, Hartgerink JD, Schmalz G. Scaffolds for dental pulp tissue engineering. *Adv Dent Res* 2011;23:333-9.
22. Dirix G, Monsieurs P, Dombrecht B, Daniels R, Marchal K, Vanderleyden J, et al. Peptide signal molecules and bacteriocins in Gram-negative bacteria: A genome-wide in silico screening for peptides containing a double-glycine leader sequence and their cognate transporters. *Peptides* 2004;25:1425-40.
23. Kikuchi M. Geometric design method for class I inlay cavity. *Dent Mater J* 2010;29:637-41.

# A SIMPLE METHOD OF REHABILITATING AN ACQUIRED MAXILLECTOMY DEFECT PATIENT WITH HOLLOW BULB OBTURATOR: A CASE REPORT

\*Dr. Dhanya Preman, \*\*Dr. Sheejith M., \*\*\*Dr. Swapna C., \*\*\*\*Dr. Ranjith M.

## Abstract

The most commonly seen intraoral defect is the one affecting maxilla. The situation becomes troublesome for the patient if there is oro antral or oro nasal communication. These defects can either be congenital or acquired. These defects create large openings in the palate and/or the surrounding structures. Obturators are used to close or seal these defects to restore proper mastication, speech, deglutition, and esthetics. The prosthetic rehabilitation of patients with maxillectomy defects offers a significant challenge to the Prosthodontist. This article presents a case report describing simple technique for fabricating hollow bulb obturator in a completely edentulous patient with a large defect in hard palate crossing midline and involving alveolar ridge and maxillary tuberosity on right side with bilateral nasal communication.

**Key Words:** maxillectomy defects, hollow bulb obturator, carcinoma

**Corresponding Author:** Dr. Dhanya Preman

*\*Post Graduate Student, \*\*Professor & Head, \*\*\*Professor, \*\*\*\*Reader, Dept. of Prosthodontics, Crown & Bridge, KMCT Dental College, Manassery, Kozhikode 673602, Kerala, India*

## Introduction

Deformity of face and associated structures, be it congenital or acquired has a negative influence on the psychological well being of man. It imparts a mental trauma to the patient and the dear and near ones. The common etiologies for acquired defects of the oral cavity are cancer and traumatic injury.<sup>1</sup> Tumors occurring in the maxilla and associated structures can be benign or malignant, but the ablative surgery due to malignancy may remove varying portions of the maxilla. This loss of the maxilla results in a series of defects which can affect patients speech, esthetics, mastication and deglutition. Post-surgical maxillary defects pre-dispose the patient to hypernasal speech,

fluid leakage into the nasal cavity, and impaired masticator function.

The prosthodontic rehabilitation of patients with acquired defects of the maxilla after surgical resection is the complete responsibility of a maxillofacial prosthodontist. He has to recreate an artificial barrier between the cavities and thus restore the functional capabilities of speech, mastication and swallowing.<sup>2</sup>

Obturator is derived from a Latin word 'obturare' which means 'to stop up'. Obturator is defined as a prosthesis used to close a congenital or acquired tissue opening, primarily of the hard palate and/or



contiguous alveolar structures. Prosthetic restoration of the defect often includes use of surgical obturator, intrim obturator and definitive obturator-GPT 8.

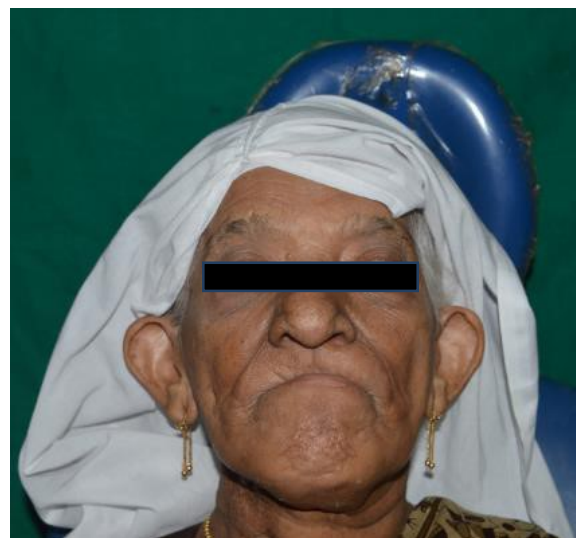Prosthodontic management of palatal defects has been employed for many years. The history of maxillary obturator prostheses is well documented. Ambroise Pare was the first to use artificial means to close a palatal defect as early as the 1500s. The early obturators were used to close congenital rather than acquired defects. Claude Martin described the use of a surgical obturator prosthesis in 1875. Fry described the use of impressions before surgery in 1927, and Steadman described the use of an acrylic resin prostheses lined with gutta-percha to hold a skin graft within a maxillectomy defect in 1956 (Desjardins, 1978; Huryn&Piro, 1989).

Single-piece hollow obturator is more hygienic, esthetic, and simple to fabricate. If the defect is large with more soft tissue undercuts, then a two-piece obturator is preferred<sup>[2]</sup>. But if the defect is large two piece obturator is planned. The prosthesis being located in the maxilla, the retention is affected by naturally existing gravitational force acting on it. Hence, light-weight prosthesis (hollow bulb) will not only combat this problem but also enhance the resonance of speech.<sup>3</sup>

### Case report

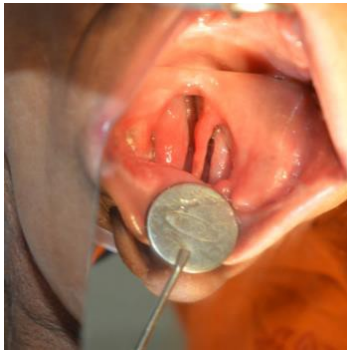A 72 year old female patient was referred to the Department of Prosthodontics from

MVR Cancer Center and Research Institute for the maxillofacial rehabilitation following surgical removal of Carcinoma of hard palate 6 months back. The chief complaint of the patient was food coming out through nose and difficulty in eating due to missing teeth and loss of clarity in speech. Medical history stated that she has undergone surgical resection for Carcinoma palate 6 months back and undergone radiation therapy for the same. She was denture wearer for past 10 years and now she is unable to use her denture.



**Fig 1:Extra oral view**

Intra oral examination showed Completely edentulous maxillary arch with acquired defect involving right side of hard palate crossing midline and right side of alveolus with communication between oral and bilateral nasal cavity. She is Partially edentulous in relation to 31, 35, 36, 37, 38, 41, 46, 47. Caries irt 45 and generalized attrition of mandibular teeth.



**Fig 2: Intra oral view**

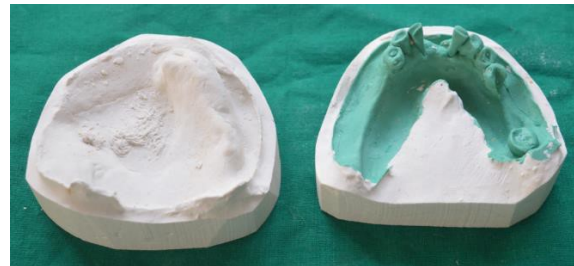
The surgical site had undergone satisfactory healing. Diagnosis is Completely edentulous maxillary arch with Umino et al I c defect. Mandibular arch with Kennedy Class II modification 2.

Treatment options available were Endodontic management of 45 followed by FPD irt 41,31,46,47 and Implant supported crown irt 35,36,37 and Maxillary obturator replacing maxillary dentition retained with implants. Other alternative was Maxillary hollow bulb obturator replacing maxillary dentition and mandibular removable partial denture irt to missing 31, 35, 36, 37, 38, 41, 46,47.

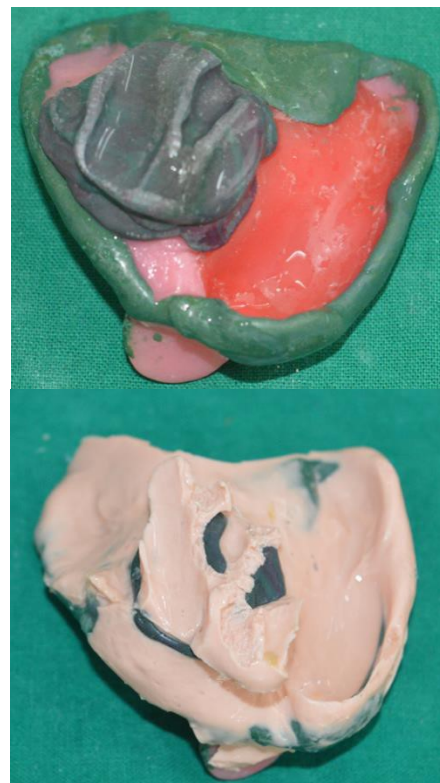
The patient opted for second option since she needed a simple treatment. Hence a conventional complete denture with hollow bulb obturator was planned in the maxillary arch and removable partial denture in the mandibular arch.

Preliminary impression of maxillary and mandibular arches were made with hydrocolloid impression material and casts were poured. Special tray was fabricated. Border molding was done with low fusing impression compound and the impression of the surgical defect area was obtained using

Admix technique. Since the alveolar ridge and maxillary tuberosity on the right side was surgically removed, care was taken to obtain adequate retention from the undercut present in anterior region of the left alveolar ridge.



**Fig 3: Preliminary casts**

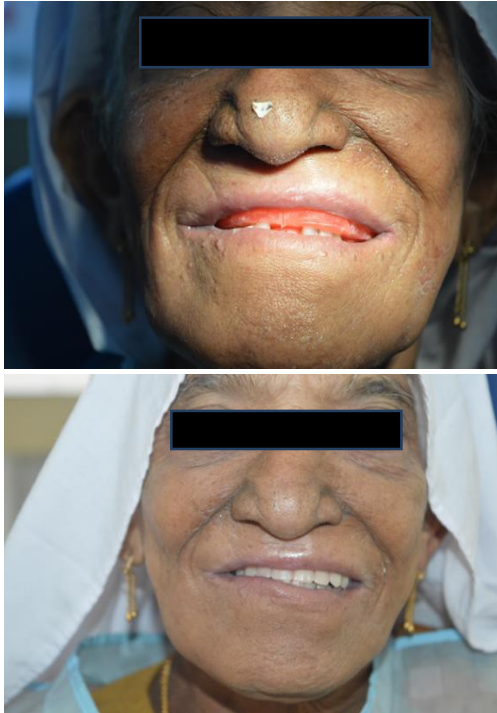

**Fig 4 & 5: Border molding and secondary impression of maxillary arch**

Jaw relation was done and teeth were arranged following the arch form of left alveolar ridge. Try in was done. Occlusion,



esthetics and phonation was assessed. Patient acceptance was obtained in terms of esthetics.

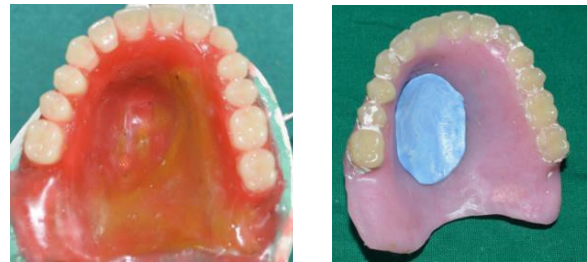

**Fig 6 & 7: Jaw Relation & Try in**

After try in the denture was waxed up. After processing the maxillary complete denture laboratory steps to make the lid for the hollow bulb was initiated. A heavy body silicon putty material was adapted to the walls filling the hollow part of the denture. Then the putty material was removed from the hollow cavity and the shellac base plate was separated from the putty material. This shellac forms the wax pattern of lid which was invested in dental plaster.

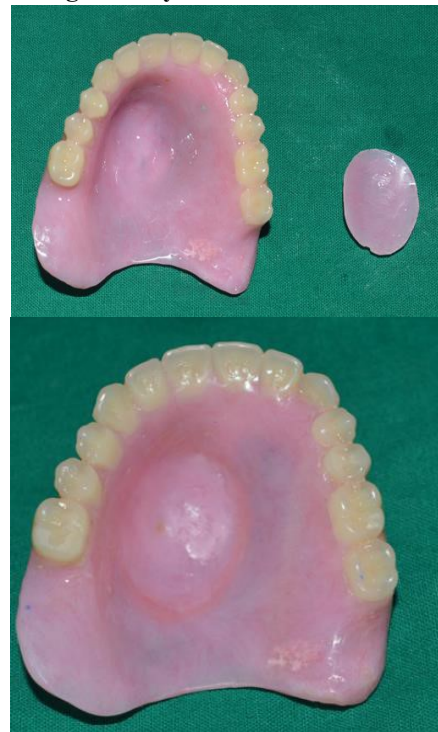Acrylization of the lid was done. The acrylized lid was then polished and trimmed to closely adapt to the walls of hollow bulb. A custom made lid made of heat cure acrylic has certain advantages over the conventional method of covering the hollow bulb with lid

made of self cure. Leaching out of residual monomer can cause irritation of the soft tissue, can impart bad taste and colour change over a period of time. These demerits are avoided by using lid processed with heat cure.



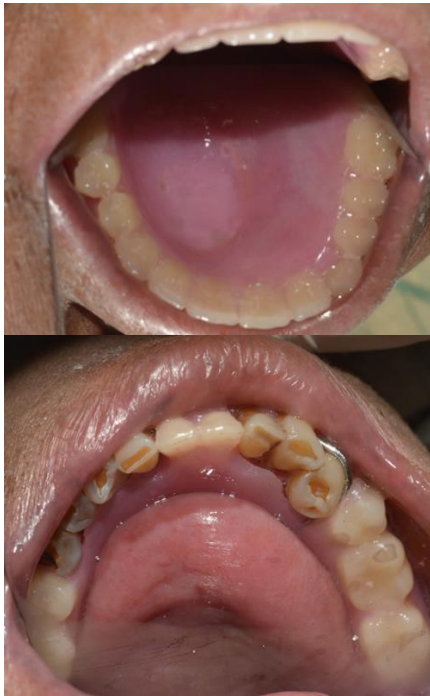**Fig 8: waxed up denture**

**Fig 9: Putty index of hollow bulb**



**Fig 10a & b :Processed complete denture and lid and lid attached to complete denture**

Maxillary complete denture with hollow bulb obturator and mandibular removable partial denture prosthesis insertion was done. Occlusion, esthetics, speech were reassessed. Post insertion instructions were given. The patient satisfaction was assessed.



**Fig 11a &b: Intra oral post insertion view**

Patient was reviewed after one week and one month. She reported that her normal dietary habits were restored, doesn't have to wetting of clothes frequently as earlier due to food spillage from her nose. She was happy that her speech is now clear and understandable. She can smile better now. The prosthesis helped her improve her life which contributed to the well being of the patient and people surrounding her.



**Fig 12: Extra oral -Post insertion view**

## Conclusion

One of the primary objective of rehabilitation of maxillary defect by using the obturator is the recreation of partition between the oral and nasal cavities.<sup>4-8</sup> Successful replacements of such partition improves deglutition and enhances speech intelligibility. Restoration of esthetics is achieved by the replacement of missing teeth.<sup>9,10</sup> A two-piece maxillary obturator is fabricated having a silicon bulb attached with the help of acrylic press-studs on the maxillary plate has been reported by Dholam et al.<sup>11</sup> The use of the resilient attachments post maxillectomy has been described by Devlin et al.<sup>12</sup> Obviously there are evidence which states that obturator significantly improves the quality of life of maxillectomy patients and improves their self-esteem.<sup>13</sup>

## References

1. Wu YL, Schaaf NG. Comparison of weight reduction in different designs of solid and hollow obturator prostheses. *J Prosthet Dent* 1989;62:214-7.
2. Chalian VA, Barnett MO. A new technique for constructing a one-piece hollow obturator after partial maxillectomy. *J Prosthet Dent* 1972; 28:448-53.
3. Schwartzman B, Caputo AA, Beumer J. Gravity induced stresses by an obturator prostheses. *J Prosthet Dent* 1990; 64:466-8.
4. Bidra AS, Jacob RF. Classification of maxillectomy defects: A systematic review and criteria necessary for a universal description. *J Prosthet Dent*. 2012;10(7): 261-70.
5. Srinivasan M, Padmanabhan TV. Rehabilitation of an acquired maxillary defect. *J Indian Prosthodont Soc* 2005;5: 155-7.

6. Pervez E et al. An innovative technique of fabrication of hollow obturator for a case of hemi-maxillectomy *Annals of Dental Specialty* 2015;3(1):29-32.
7. Rajani D et al, A Hollow Bulb Obturator For Maxillary Resection In A Completely Edentulous Patient. *Journal of Clinical and Diagnostic Research*. 2011; 5(1): 157-62.
8. Jain A R et al. Cast Retainer Hollow Bulb Obturator for a Maxillary Defect -A Case Report. *Int Jo Dent Sci Res*. 2014; 2(6): 164-7.
9. Ahila A et al. Comparison of obturator design for acquired maxillary defect in completely edentulous patients. *Ind J Dent Res* 2011;22(1):161-3.
10. Okay DJ, Genden E, Buchbinder D, Urken M. Prosthodontic guidelines for surgical reconstruction of the maxilla: A classification system of defects. *J Prosthet Dent* 2001;86:352-63.
11. Dholam KP, Sadashiva KM, Bhirangi PP. Rehabilitation of large maxillary defect with two-piece maxillary obturators. *J Can Res Ther* 2015;11:664.
12. Devlin H, Barker GR. Prosthetic rehabilitation of the edentulous patient requiring a partial maxillectomy. *J Prosthet Dent* 1992;67:223-7.
13. Riaz N, Warriach RA. Quality of life in patients with obturator prostheses. *J Ayub Med Coll Abbottabad* 2010;22:121-5.

## “BE WISE ON EARLY RISE”-NATAL AND NEONATAL TEETH

\*Dr. P Prathyusha,\*\*Dr.Amith Adyanthaya,\*\*Dr.Marium Raheema,  
\*\*\*Dr.Aswathi Krishna K ,\*\*\*\*Dr.Hiba Ummer, \*\*\*\*\*Dr.Lasna MT

### Abstract

Natal and neonatal teeth are of the rare developmental variations seen in infants. Many times infants are seen born with teeth which are termed as natal teeth. Other times teeth erupts with in 1<sup>st</sup> month of birth are termed as neonatal teeth. They are most commonly a part of deciduous dentition. Presence of natal tooth may lead to numerous complications. Here two case reports have been presented which include natal and neonatal teeth present in the mandibular anterior region in 9 and 31 day old infants along with its management.

**Key Words:** natal teeth, neonatal teeth, management

**Corresponding Author:** Dr. Lasna MT

*\*Professor & Head,\*\*Reader,\*\*\*Senior Lecturer,\*\*\*\*Post Graduate Student, Dept. of Pedodontics, \*\*\*\* Senior Lecturer, Dept. of Oral Pathology KMCT Dental College, Manassery, Kozhikode 673602.*

### Introduction

Physiologically 1<sup>st</sup> primary tooth shows signs of eruption approximately at 6 months of age but with wide range between 6 months to 1 year of infants life. But some teeth are found to be present even at the time of birth, termed as natal teeth or some that erupt in the neonatal period that is, within thirty days of birth, termed as neonatal teeth. Teeth erupting beyond the natal period of thirty days (i.e. erupting within 1-3.5 months) are usually referred to as early infancy teeth.<sup>1</sup> If a tooth is found at the time of birth or during early infancy, it leads to a plethora of reactions, which are combined with a lot of misconceptions. To complicate matters further, there are various difficulties encountered by both the infant as well as the mother like pain on suckling, refusal to feed, irritability etc.<sup>2</sup>

Prematurely erupted primary teeth present at birth have also been described in the literature as congenital teeth, foetal teeth, pre-deciduous teeth, premature teeth, precociously erupted teeth or dentitia praecox.<sup>3</sup>

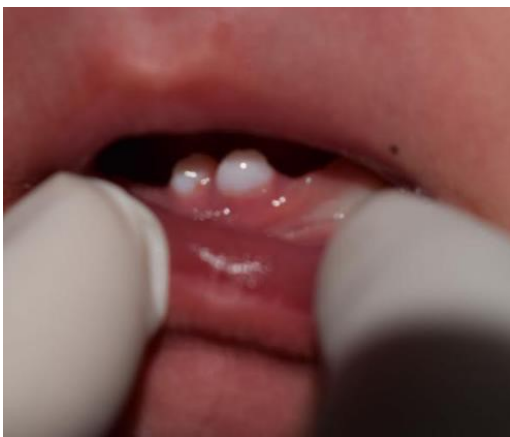Zhu and King<sup>4</sup> reported the incidence of both natal and neonatal teeth as ranging from 1:716 to 1:30000, whereas Chow<sup>5</sup> reported an incidence of 1:2000 to 1:3500. Natal teeth are encountered more often than neonatal teeth in an approximate ratio of 3:1 with a greater predilection for females.<sup>6</sup> King and Lee<sup>7</sup> reported that the teeth affected most often are the lower primary central incisors. According to the study by Bodengoff,<sup>8</sup> 85% of natal teeth are mandibular incisors, 11% maxillary incisors, 3% mandibular canines and only 1% are



maxillary canine or molar. They usually occur in pairs and the eruption of more than two natal teeth is rare.

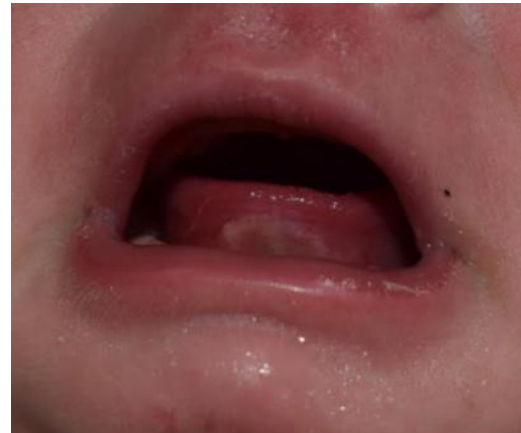**Case Report 1**

A nine day old male infant was reported to the OPD of Department of Pedodontics and Preventive Dentistry, KMCT dental college, Calicut with complaint of two loose front teeth in the lower jaw noticed by mother two days after birth. She gave the history of difficulty in feeding. On examination, two mobile natal teeth were found in the mandibular anterior region that posed the danger of aspiration (Fig;1). An ulcer of size 2×2 cm was present at the tip and ventral surface of tongue (Fig;2). Hence, after discussion with parent a decision was made to extract the tooth following consultation with the Pediatrician with regard to the need of supplementation of Vitamin K.



**Fig. 1: Natal teeth**

After administration of Vit K 1mg stat the teeth were extracted under infiltration local anesthesia. Hemostasis was achieved (Fig;3) and the medication was prescribed in the form of analgesic drops.

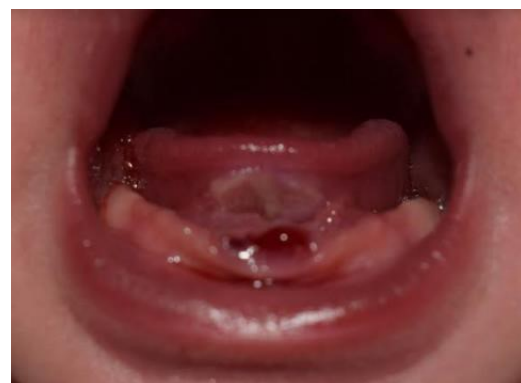

**Fig. 2: Ulceration**

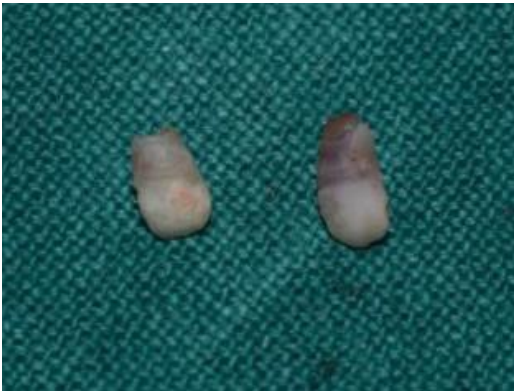The patient was reviewed after 1 week and the healing was uneventful. One of the extracted teeth clinically showed a crown with short root and the other one was a shell like tooth structure devoid of root.

**Histopathological Report**

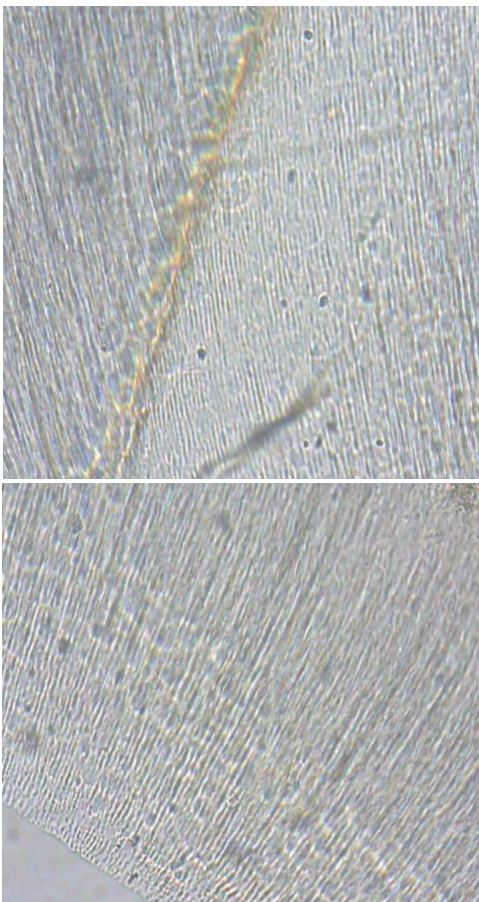
Ground sections of the extracted teeth were prepared. Microscopic examination of the ground section revealed enamel and dentin. Enamel showed enamel lamellae and tuft. The dentinoenamel junction was less scalloped. Dentin exhibited irregular dentinal tubules and large areas of interglobular dentin. These histological features depicted that the teeth are primary central incisors which have erupted prematurely. (Fig. 5a, b)



**Fig. 3: Extraction done**



**Fig. 4: Extracted teeth**

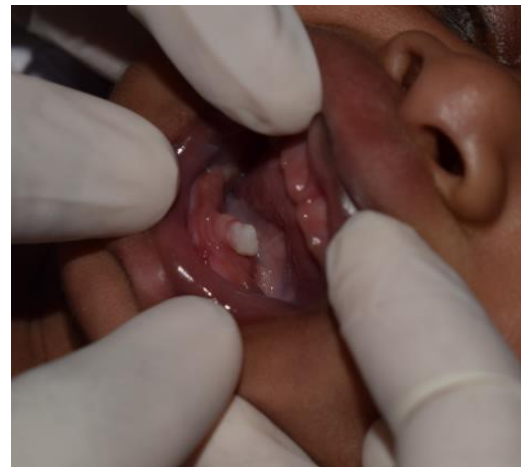

**Fig. 5a&b: Ground sections**

### Case Report 2

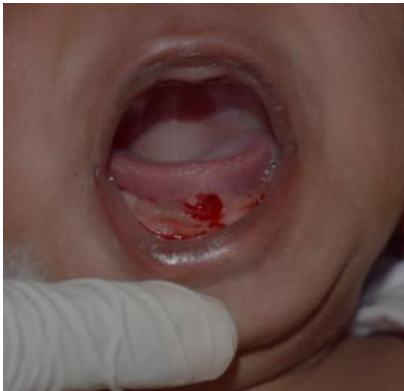In another case, a thirty one days old female infant was reported to the Department of Pedodontics and Preventive Dentistry at KMCT Dental College, Calicut with

complaint of loose milk tooth in the lower front region of the jaw, noticed by mother twelve days after birth. She also gave the history of difficulty in feeding & the infant was irritable. Patient's medical history and family history were within normal limits. On examination single mobile neonatal tooth was found in the mandibular anterior region. It was opaque white in colour (Fig;6).As the tooth was very mobile it posed a danger of aspiration. Hence, after discussion with parent a decision was made to extract the tooth. Pediatric consultation was sought for vitamin. K supplementation. Vit K was not recommended as the infant was 31 day old.

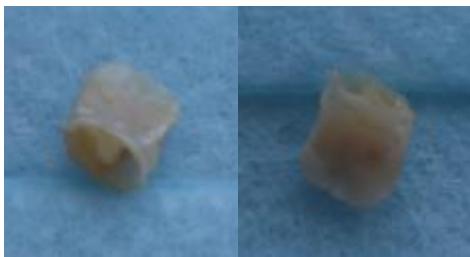

**Fig. 6: The mobile tooth**

Extraction of the tooth was carried out under topical local anesthesia. (Fig. 7) considering the age and mobility of the teeth. Post extraction haemostasis was achieved and the medication was prescribed in the form of analgesic drops. The patient was reviewed after 1 week and the healing was uneventful, and the tongue ulcer resolved satisfactorily. The extracted tooth showed a crown having normal size with no root. (Fig: 8a, b)



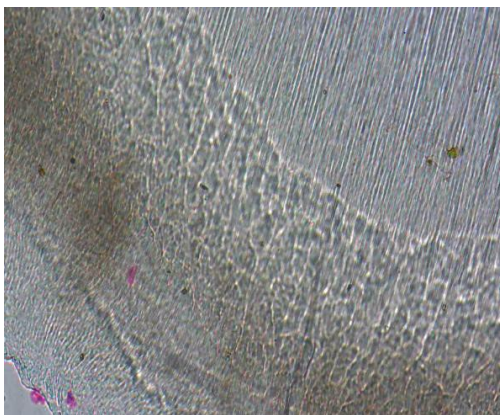
**Fig. 7: Post extraction view**



**Fig. 8a&b: Incisal and apical view**

### Histopathological Report

Ground sections of the extracted tooth was done. Microscopic examination of the ground section revealed enamel and dentin. Enamel showed enamel lamellae. The dentinoenamel junction was less scalloped. Dentin exhibits irregular dentinal tubules and large areas of interglobular dentin. (Fig 9). These histological features depicted that it is a primary central incisor which has erupted prematurely.



**Fig 9: Ground section of the tooth**

### Discussion

Natal and neonatal teeth are most commonly a part of deciduous dentition and erupt in the same position as that of primary teeth in the arch. The natal tooth is made up of enamel, dentin and pulp with or without root.

In 1997, Helbling classified natal teeth into 4 types based on the clinical appearance:<sup>10</sup>

- i. Shell-shaped crown, poorly fixed to the alveolus by gingival tissue and absence of a root.
- ii. Solid crown, poorly fixed to the alveolus by gingival tissue and little or no root.
- iii. Eruption of the incisal margin of the crown through the gingival tissues.
- iv. Edema of gingival tissue with an unerupted but palpable tooth.

There have been many postulates including hypovitaminosis, hormonal stimulation, trauma, febrile states and syphilis for the presence or aetiology of natal teeth. Even hereditary factors or an underlying syndrome could predispose to its occurrence. But the current concept suggests that the presence of these teeth is attributed to a superficial position of developing tooth germ, which predisposes the tooth to erupt early.<sup>6</sup> Boyd and Miles<sup>9</sup> reported that the erupted primary central incisors were not located in an alveolus but slightly below on the surface of the alveolar bone, very much above the germ of the permanent successor.



Natal and neonatal teeth are frequently found in association with developmental abnormalities and recognized syndromes. These syndromes include Adrenogenital syndrome, Cleft lip and palate, Craniofacial dysostosis, Craniosynostosis syndromes, Ectodermal dysplasia, Ellis-van Creveld syndrome, Epidermolysis bullosa simplex, Hallerman Streiff syndrome, Jadassohn-Lewandowsky syndrome, Multiple steacystoma, PallisterHall syndrome, Pfeiffer syndrome, Pierre Robin syndrome, Polydactyly type II, Rubinstein-Taybi syndrome, Sotos syndrome, Steatocystoma multiplex, Van derWoude syndrome, Walker-Warburg syndrome and Wiedeman-Rautenstrauch syndrome.<sup>11</sup>

The presence of natal and neonatal teeth would be a source of doubt about the treatment plan. In deciding whether to maintain these teeth in the oral cavity, some factors should be considered, i.e, degree of mobility, inconveniences during suckling, interference with breast feeding, possibility of traumatic injury and whether the tooth is part of the normal dentition or is supernumerary. If the tooth is supernumerary, then the treatment of choice is extraction. When the tooth/teeth are excessively mobile, extraction is indicated owing to the risk of exfoliation and swallowing or aspiration. However, when reviewing the literature, no reported cases of aspiration of natal or neonatal teeth were found. In one study, only 38% of natal and

neonatal teeth exfoliated in the first year of life. When natal teeth are only slightly mobile, they often stabilize soon after eruption.<sup>6</sup>

For extraction of natal or neonatal teeth would be in cases where there is minimal gingival attachment, as in this case report, it will likely be possible to achieve adequate soft tissue anesthesia with the application of topical anesthetic. In this scenario, the authors recommend that no curettage of the extraction site be performed. In most cases, this treatment will be adequate and the child will not develop residual natal or neonatal teeth. Where it is possible, this conservative initial treatment will allow most children to avoid exposure to injectable local anesthetic and a lengthier, more stressful surgical procedure associated with curettage of the area. However, recognizing that the risk of residual tooth formation is approximately 9.1%, the parents should be informed of the need for regular follow-up with a dentist. They should also be informed that in the event of residual tooth formation, a second surgical procedure will be required.

For extraction of natal or neonatal teeth in cases where there is more significant gingival attachment, topical anesthetic may be followed with a small amount of an injectable local anesthetic. Only in these cases, do the authors recommend routinely providing simultaneous curettage of the area. Prophylactic administration of vitamin

K (0.5—1.0 mg, i.m.) is advocated because of the risk of hemorrhage as the commensal flora of the intestine might not have been established until the child is 10 days old, and since vitamin K is essential for the production of prothrombin in the liver.<sup>6,12</sup> Need for the Vitamin K prophylaxis comes down beyond 10 days.

The most common complaint of natal and neonatal teeth was found to be trauma to the tongue on the tip or ventral surface, a complication referred to as Riga-Fede syndrome. It occurs in 6–10% of cases of natal teeth. It was also suggested that this ulceration could be due to the fact that the tongue in infants lies immediately between the alveolar ridge.<sup>10</sup> Kinirons in 1985 reported sublingual ulceration due to sucking. The ulcerations caused by the natal teeth could be managed by rounding of the incisal edges of the teeth. If extraction is not advocated, in cases of mild-to-moderate irritation to the tongue, such treatment may suffice. If the ulcerated area is large and denuded, however, even the reduced incisal edge may still contact and traumatize the tongue during suckling to an extent enough to delay healing, which suggests that extraction may be advised.<sup>1</sup>

### Conclusion

Natal and neonatal teeth are rare occurrences in the oral cavity and proper evaluation and diagnosis are crucial to provide the best treatment option. Pediatricians are usually

the first to detect these teeth and early consultation with the dentist can prevent complications. The decision to maintain or extract these teeth should be assessed in each case.

### References

1. Akash Ardeshana, Seema Bargale, Anuradha Karri, Bhavna Dave; Dentitia Praecox - Natal Teeth: A Case Report and Review. *J Applied Dent Med Sci* 2016; 2(1): 44-51.
2. Rao RS, Mathad SV. Natal teeth: Case report and review of literature. *J Oral Maxillofac Pathol* 2009; 13: 41-6.
3. Nirmala SVSG, Prabhu RV, Veluru S, Tharay N, Kolli NK, et al. Natal Teeth - A Case Report with Decision Support System. *J Pediatr Neonatal Care* 2015;2(3): 00073.
4. Zhu J, King D. Natal and neonatal teeth. *ASDC J Dent Child* 1995; 62: 123–8.
5. Chow MH. Natal and neonatal teeth. *J Am Dent Assoc* 1980;100:215–6.
6. Vishal Khandelwal, Ullal Anand Nayak, Prathibha Anand Nayak, Yash Bafna; Management of an infant having natal teeth. *BMJ Case Rep.* 2013; 2013: bcr2013010049.
7. King NM, Lee AM. Prematurely erupted teeth in newborn infants. *J Pediatr* 1989; 114: 8079.

8. Bodenhoff J, Gorlin RJ. Natal and neonatal teeth: folklore and fact. *Pediatr* 1963; 32: 1087–93.
9. Boyd JD, Miles AE. Erupted teeth in ciclops faetus. *Br Dent J* 1951;91:173.
10. Ghadah A. Malki, Emad A. Al-Badawi, and Mohammad A. Dahlan; Natal Teeth: A Case Report and Reappraisal. *Case Reports in Dentistry* 2015, Article ID 147580-4.
11. Firoza Samadi, Prashant Babaji, Sonali Saha, Ashish Katiyar, Swati Chow-dhry; Natal Teeth: Report of Two Cases and Review of Literature. *International Journal of Oral and Maxillofacial Pathology*;2011;2(1): 33-6.
12. Rusmah M. Natal and neonatal teeth: a clinical and histological study. *J Clin Pediatr Dent* 1991;15:251–3.

## ENDODONTIC MANAGEMENT OF MANDIBULAR FIRST MOLAR WITH RADIX ENDOMOLARIS & FIVE CANALS: A CASE REPORT

\*Dr. Ramesh Kumar M, \*\*Dr. Nasleena K., \*\*\*Dr. Elsy P. Simon,  
\*\*\*\*Dr. Ravi S.V, \*\*\*\*\*Dr. Mohammed Ashik. P

### Abstract

The knowledge of variations in root canal morphology significantly affects the success of endodontic treatment. This article presents the endodontic management of a unique case of mandibular molar with an additional distolingual root with two canals and radix endomolaris which is quite uncommon. Mandibular molars can sometimes present a variation called radix endomolaris, wherein the tooth has an extra root attached to its lingual aspect. Accurate diagnosis and careful application of clinical endodontic skill can favorably alter the prognosis of treatment.

**Key Words:** radix endomolaris, management, case report

**Corresponding Author:** Dr. Nasleena K

*\*Professor & Head, \*\*Post Graduate Student, \*\*\*Professor, \*\*\*\*Reader, \*\*\*\*\*Senior Lecturer Dept. of Conservative Dentistry, KMCT Dental College, Manassery, Kozhikode 673602*

### Introduction

Predictable success in endodontic treatment calls for a thorough understanding of root canal morphology and anatomy which in turn will facilitate the debridement, disinfection and obturation of the root canal. Thus, it is mandatory for the clinician to have knowledge of not only the normal anatomy but also its variations.<sup>1</sup> Mandibular molars generally have two canals in the mesial root and one or two canals in the distal root.<sup>2</sup> Studies have shown an incidence of five canals in mandibular first molar to show a variation of 1 and 15% where as three distal canals to be reported of about 0.6%.<sup>3,4</sup> This case report describes the diagnosis and successful management of a case of mandibular first molar with this unusual morphological variation of three

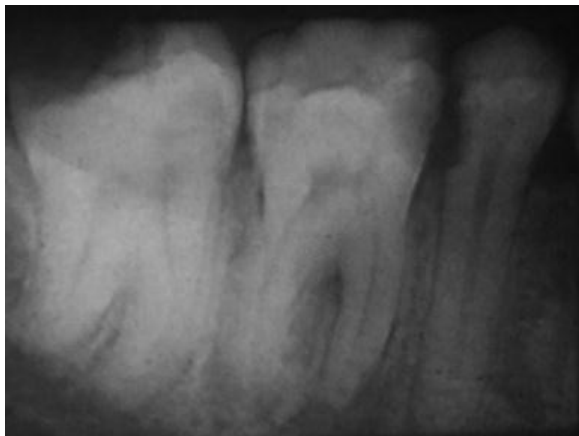
distal canals. The presence of two distal canals in distobuccal root and additional distolingual root demonstrates a rare anatomical configuration.

### Case Report

A 24-year-old male patient came to the clinic with the complaint of pain in the posterior right mandibular region for the past two weeks. The pain was initially spontaneous and was later triggered by many factors, especially cold. His past medical history was found to be non-contributory. Clinical examination revealed a carious right mandibular first molar with tenderness on percussion. The clinical findings, vitality tests and radiographic findings led to a diagnosis of acute apical

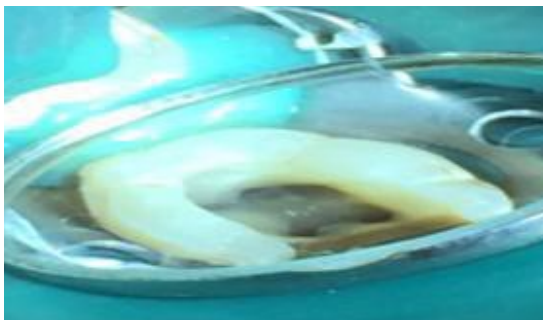periodontitis of the right mandibular first molar, necessitating endodontic therapy.

Radiographic evaluation of the involved tooth did not reveal any unusual anatomy (Fig. 1). The tooth was anesthetized using 2% lignocaine with 1: 80,000 adrenaline (Lignox, Indoco Remedies Ltd., India) and isolated using rubber dam.



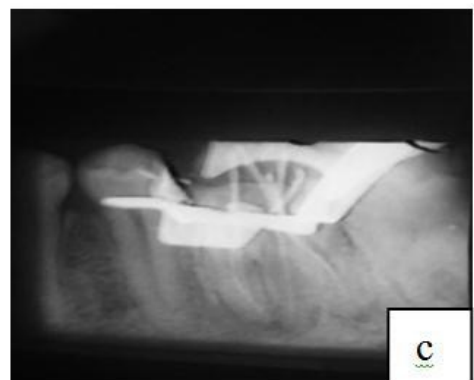
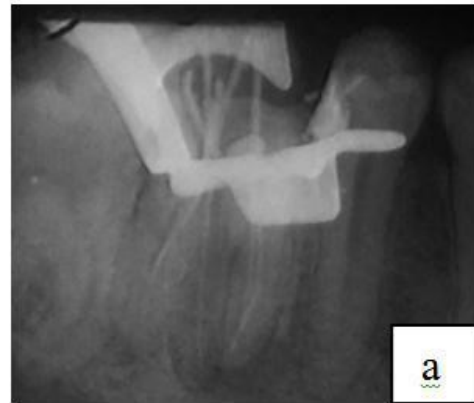
**Fig. 1: Radiographic evaluation of the tooth**

Endodontic access cavity was established. For the straight line access, gates gliden drills were used with crown down method to enlarge the orifices. Inspection of the pulp chamber revealed five canal orifices. (Fig. 2) canal patency was checked with number 10 k-file (Mani, Inc.; Tochigi, Japan).



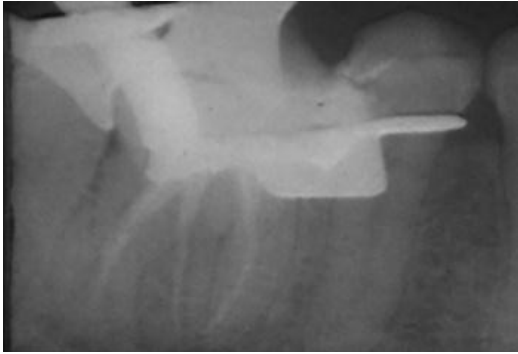
**Fig. 2: Inspection of the pulp chamber revealed five canal orifices**

Working length was determined with an apex locator and confirmed by a radiograph. Irrigation was done using 5% sodium hypochlorite to remove debris and bacteria. Five canals were instrumented using k files till apical preparation #25 size (Fig. 3a, 3b, 3c).



**Fig. 3a, 3b, 3c: Five canals were instrumented using k files till apical preparation #25 size**

Patient was then recalled after a week. The root canals were then dried with paper points, and obturated with cold, laterally condensed gutta-percha and ah plus resin sealer (dentsply) (Fig. 4).



**Fig. 4: The root canals were obturated with cold, laterally condensed gutta-percha**

### Discussion

Studies have reported Indian population to have an incidence of three canals in distal root to be 1.7%; 0.2 % in Senegalese population; 1.7% in Turkish population; 0.7% in Burmese population; 1.6% in Thai population; and in Sudanese population 3% incidence has been reported.<sup>5</sup> Radix endomolaris has been reported to occur with a frequency of 0.2-32% in different populations.<sup>6</sup> The most commonly seen variations of root canal system of mandibular first molar is presence of middle mesial canal is incidence of 1-15%<sup>3,4</sup> where as presence of disto buccal root with two canals and radix endomolaris is rare.

Radix endomolaris is commonly found as a short conical extension to a full length root located distolingually the extension of root may be unilateral or bilateral and may or may not contain pulpal tissue.<sup>7</sup> Due to the high incidence of curvature, precurved

filling is required to establish a glide path to the apical segment; therefore niti rotary files for biomechanical preparation is required.<sup>8</sup>

One of the most important causes of endodontic treatment failure is the incomplete obturation of the root canal system.<sup>9</sup> Important cause attributed to the failure of endodontic treatment has been reported by vertucci as missing canals.<sup>10</sup> Therefore, the correct location, thorough debridement, shaping, cleaning and obturating the entire root canal system are indispensable procedures.

### Conclusion

Successful endodontic treatment requires knowledge of root canal anatomy and requires a correct diagnosis and careful inspection. The morphological variations in pulpal anatomy must always be evaluated before beginning treatment. The case presented shows distobuccal root with two canals and radix endomolaris in mandibular molars is one such variations. Even though the frequency is rare, each case should be evaluated carefully both clinically and correlated radiographically.

### References

1. Baratto-Filho F, Fariniuk LF, Ferreira EL, Pecora JD, Cruz-Filho AM, Sousa-Neto MD. Clinical and macroscopic study of maxillary molars with two palatal roots. *Int Endo J* 2002 Sep 1; 35(9): 796-801.
2. Ahmed HA, Abu-bakr NH, Yahia NA, Ibrahim YE. Root and canal morphology of permanent mandibular

- molars in a Sudanese population. *Int Endo J.* 2007 Oct 1; 40(10):766-71.
3. Adanir N. An unusual maxillary first molar with four roots and six canals: a case report. *Aus Dent J.* 2007 Dec 1; 52(4):333-5.
  4. Fabra-Campos H. Unusual root anatomy of mandibular first molars. *J Endo.* 1985 Dec : 11(12):568-72.
  5. Kottoor J, Sudha R, Velmurugan N. Middle distal canal of the mandibular first molar: a case report and literature review. *Int Endo J.* 2010 Aug 1;43(8):714-22.
  6. Attam K, Nawal RR, Utneja S, Talwar S. Radix entomolaris in mandibular first molars in Indian population: a review and case reports. *Case reports in Dentistry.* 2012; 2012.
  7. Reichart PA, Metah D. Three-rooted permanent mandibular first molars in the Thai. *Com Dent Oral Epi.* 1981 Aug 1;9(4):191-2.
  8. Calberson F L, De Moor R J, Deroose CA. The radix entomolaris and paramolaris: clinical approach in endodontics. *J Endo.* 2007 Jan 1; 33(1): 58-63.
  9. Ingle J I, Bakland LK, Baumgartner JC, Ingle's Endodontics, 6th edition, BC Decker Inc, 2008:1053.
  10. Vertucci FJ. Root canal anatomy of the human permanent teeth. *Oral Surg Oral Med Oral Pathol.* 1984 Nov 1; 58(5): 589-99.



## ACHIEVEMENTS

CDE on essentials of CBCT was conducted by the Department of Oral Medicine and Radiology on 21-02-18. The faculty for the CDE were Dr. Vivek G, Dr. Niyas, and Dr. Shireen.

CDE on Bite registration for functional appliances was conducted by Department of Orthodontics. The faculty was Dr. Sreejith Kumar, Professor & Head, Dept. Orthodontics, Govt. Dental College, Alapuzha.



CDE on Aesthetic and Post endodontic restorations-current choices by Dr. Narashimha Bharadwaj, Former Professor & Head, Sathyabama University Dental College and Hospital, Chennai on 21-04-18.

